# MicroRNA-150 Is up-regulated in Extranodal Marginal Zone Lymphoma of MALT Type

NIKLAS GEBAUER[1], JOHANNES KUBA[1], ANDREA SENFT[2], ARNE SCHILLERT[2], VERONICA BERNARD[1] and CHRISTOPH THORNS[1]

[1]*Department of Pathology, Reference Center for Lymph Node Pathology and Hematopathology, University Hospital of Schleswig-Holstein, Campus Luebeck, Luebeck, Germany;*
[2]*Department of medical Biometrics and Statistics, University of Lübeck, Luebeck, Germany*

**Abstract.** *Background: The mechanisms promoting malignant transformation from chronic Helicobacter pylori-gastritis to gastric extranodal marginal zone lymphoma (MALT lymphoma) are insufficiently characterized. This follow-up study aimed to validate candidate microRNAs (miRs) in the process of neoplastic transformation. Materials and Methods: MicroRNA expression signatures (n=20) were generated for a total of 60 cases of gastric lesions ranging from Wotherspoon 0-5 employing a quantitative real-time polymerase chain reaction (PCR) approach. Morphological and immunohistochemical characterization of the cohort was supplemented by PCR-based immunoglobulin heavy chain recombination studies. Results: Quantitative expression of miR-150, miR-142.3p, miR-375 and miR-494 was significantly de-regulated in samples from MALT lymphoma compared to those from gastritis. Conclusion: The previously reported up-regulation of miR-150 in marginal zone lymphoma of MALT type was verified in an independent cohort of lymphoma samples employing a modified methodology. This further substantiates the role of miR-150 as a potential oncomiR in MALT lymphoma.*

Extranodal marginal zone lymphoma of mucosa-associated lymphoid tissue (MALT) type constitutes a rare form of low-grade non-Hodgkin's lymphoma of B-cell lineage, with an annual incidence of approximately 0.5 to 1 per 100,000 (1, 2). Despite the gastrointestinal tract (stomach) being the most common site of manifestation (>50%) other localizations including skin, ocular adnexa and lung have been reported (3). It has been shown that *Helicobacter pylori* is an important stimulus in the pathogenesis of gastric MALT lymphoma (4, 5) and similar pathophysiological mechanisms have been proposed for ocular adnexal MALT lymphoma and *Chlamydia psitaci*, immunoproliferative small intestinal disease (IPSID) and *Campylobacter jejuni*, MALT lymphoma of the fallopian tube and *Acinetobacter* spp. as well as cutaneous MALT lymphoma of the skin and *Borrelia burgdorferi* (6, 7). Histopathological diagnosis of gastric MALT lymphoma in the context of morphological overlap between reactive or inflammatory changes during progressive malignant transformation is considered difficult. Most commonly, the score-based classification system as proposed by Wotherspoon *et al*. supplemented by molecular clonality assessment of the B-cell population is employed (8, 9). In cases of *Helicobacter pylori*-associated gastric MALT lymphoma, *H. pylori* eradication therapy can induce sustained remission (10, 11). The most frequently detectable chromosomal aberration in gastric MALT lymphoma [t(11;18)(q21;q21)] affecting the *MALT1* gene locus, however, coincides with resistance to *H. pylori* eradication therapy (11). Both radiation and local surgical treatment are viable options often followed by complete remission or prolonged disease-free intervals in these cases (3). Despite the well-established link between *H. pylori*-associated gastritis and MALT lymphoma, the mechanisms driving the progressive transformation of normal mucosa to lymphoma are insufficiently characterized at the molecular level. Over the past decade, microRNAs have emerged as a key element in the epigenetic regulation of gene expression (12). An involvement of these small non-coding RNAs in numerous biological processes, including cell growth, differentiation, apoptosis and pathogenesis of malignant neoplasia, by down-regulating one or several genes by means of translational repression and target degradation has been identified (13, 14). Quantitative expression of microRNAs appears to differ between normal and neoplastic tissues and it is believed that specific microRNA profiles exist for all types of tissues and

*Correspondence to:* Niklas Gebauer, Institut für Pathologie, Universität zu Lübeck, Ratzeburger Allee 160, D-23538 Lübeck, Deutschland. Tel: +49 4515002717, Fax: +49 4515003328, e-mail: niklas.gebauer@uksh.de

*Key Words:* MicroRNA, gastritis, MALT, lymphoma, malignant transformation.

Table I. *Histological scoring of lymphoid infiltrations in the gastric mucosa according to Wotherspoon et al. (9).*

| Score | Histology | Interpretation | n |
|---|---|---|---|
| 0 | Few plasma cells, no lymphoid follicles | Normal mucosa | 10 |
| 1 | Clusters of lymphocytes, no lymphoid follicles, no lymphoepithelial lesions | Gastritis | 10 |
| 2 | Lymphoid follicles with mantle zone and plasma cells, no lymphoepithelial lesions | Follicular gastritis | 10 |
| 3 | Lymphoid follicles surrounded by small lymphocytes diffusely infiltrating the lamina propria with occasional intraepithelial B-cells | Suspicious, probably reactive | 10 |
| 4 | Lymphoid follicles surrounded by marginal zone cells that diffusely infiltrate the lamina propria with lymphoeithelial lesions | Suspicious, probably lymphoma | 10 |
| 5 | Dense diffuse infiltrate with prominent lymphoepothelial lesions | Lymphoma | 10 |

tumors. Moreover, distinct microRNA signatures have been characterized for certain types of inflammation, including *H. pylori*-associated gastritis (15). Additionally microRNAs are valuable as prognostic factors in various types of malignancies (16).

In a recent study, we identified microRNA expression signatures of gastric biopsies with lesions corresponding to Wotherspoon scores 0 to 5 in order to identify microRNAs which might be involved in the process of neoplastic transformation. Quantitative aberrations of several microRNAs were associated with the presence of a predominantly lymphocytic inflammatory infiltrate (*e.g.* miR-566 and miR-212) or an underlying *H. pylori* infection (*e.g.* LET7f) (15). A set of five microRNAs, namely miR-150, miR-550, miR-124a, miR-518b and miR-539, however, was revealed to be differentially expressed in gastritis as opposed to MALT lymphoma (17). An elevated expression of miR-155 was detectable in a subset of patients, which at the time we attributed mainly to the presence of an underlying *H. pylori* infection in accordance with the literature (15). Recent findings by Saito *et al.* however suggest that these expression levels may also indicate an elevated degree of resistance towards eradication therapy (18). We reasoned that these aberrantly expressed microRNAs are a potential key element in the process of malignant transformation from chronic inflammation to lymphomagenesis.

Emphasizing on the need for validation of our initial findings, in the present study, we generated microRNA signatures in a comprehensive and independent cohort of gastric MALT lymphoma samples employing an alternate methodological approach alongside a modified statistical normalization.

## Materials and Methods

*Patients.* Formalin-fixed and paraffin-embedded (FFPE) tissue biopsy samples from a total of 60 cases were retrieved from the registry of the Reference Center for Lymph Node Pathology and Hematopathology, University Hospital of Schleswig-Holstein, Campus Luebeck. All samples were collected as part of standard clinical care and the local ethics committee has approved the study.

Two experienced hematopathologists without knowledge of microRNA expression data reassessed all cases for independent pathology review. As described previously, all biopsies were re-evaluated and scored according to the criteria shown in Table I (17).

Table II. *MicroRNAs investigated in the current study.*

| |
|---|
| let-7f |
| miR-124a |
| miR-135a |
| miR-142-3p |
| miR-148a |
| miR-150 |
| miR-153 |
| miR-182 |
| miR-198 |
| miR-203 |
| miR-335 |
| miR-346 |
| miR-375 |
| miR-429 |
| miR-494 |
| miR-518b |
| miR-550 |
| miR-572 |
| miR-575 |
| miR-7 |
| RNU 6 |

*Immunohistochemistry.* Immunohistochemical studies were performed on FFPE sections according to a standard, three-step immunoperoxidase technique using an automated TechMate system (DAKO, Glostrup, Denmark) and the BrightVision Kit (ImmunoLogic, Duiven, the Netherlands). Conventional stainings (hematoxylin and eosin, and Giemsa) were supplemented by immunohistochemical reactions for CD20, CD3, CD23, CD10, cyclin D1, Ki67 and light chains (kappa and lambda).

*Immunoglobulin heavy chain recombination studies.* In cases of non-clonal light chain expression by means of immunohistochemical reactions, immunoglobulin heavy chain gene rearrangement was

Table III. *Definition of pooled tumor groups*.

| Group | Definition | Status |
|---|---|---|
| 1 | Individuals with Wotherspoon score=0 | Normal |
| 2 | Individuals with Wotherspoon score=1, 2 and those with Wotherspoon score=3, 4 which are not clonal | Gastritis |
| 3 | Individuals with Wotherspoon score=3, 4 which are clonal and those with Wotherspoon score=5 | MALT lymphoma |

assessed for clonality in two DNA samples separately obtained from FFPE specimen by Polymerase Chain Reaction (PCR) and subsequent capillary gel electrophoresis according to the BIOMED2 protocol as described for cases classified as Wotherspoon score 3 or 4 (19).

*Nucleic acid isolation and cDNA synthesis*. Total RNA was isolated from four 20-μm sections of FFPE tissues using the Ambion Recover All kit (Ambion, Austin, TX, USA) according to the manufacturer's protocol. In order to assess microRNA expression, a total of 10 ng of RNA was reverse-transcribed using the TaqMan® universal PCR master mix, No AmpErase® UNG-kit and the TaqMan® microRNA reverse transcription kit from Applied Biosystems (Foster City, CA, USA). All reactions were diluted 1:60 and stored at –20˚C.

*Quantitative real time-PCR and data analysis*. Primers and probes for quantification of microRNA expression were obtained from Applied Biosystems. Expression signatures of 20 microRNAs (Table II) and *RNU6b* were generated in triplicate employing a quantitative real-time PCR (RT-PCR) approach on a LightCycler® 480 System (Roche, Mannheim, Germany) according to manufacturer's instructions.

MicroRNA expression data were normalized using expression of *RNU6b* in triplicate. Cases with more than 15% missing values (n=1) or equivocal data on clonality for Wotherspoon score 3 and 4 (n=2) were excluded.

To identify microRNAs with changed expression values in biopsies with increasing Wotherspoon scores, Jonckheere-Terpstra trend tests (R-package "clinfun" R version 2.11.1) were performed. These analyses were also performed for samples of Wotherspoon scores 2 to 5. To compare expression values of microRNAs in gastritis (Wotherspoon scores 1, 2, and polyclonal 3 and 4) and lymphoma (monoclonal scores 3, 4, and 5), Wilcoxon–Mann–Whitney tests were used.

## Results

*Morphological, immunophenotypic and molecular features of the study group*. By means of morphological (hematoxylin and eosin, and Giemsa) and immunohistochemical investigations (CD20, CD3, CD23, CD10, cyclin D1 and MIB1) the cases enrolled in the present study were classified in accordance with the scoring criteria proposed by Wotherspoon *et al*. (9). Employed criteria and case distribution for the current study according to the Wotherspoon system are briefly summarized in Table I.

Clonality analyses of tissues of Wotherspoon scores 3 and 4 by means of immunohistochemistry for light chains kappa and lambda and by PCR for the immunoglobulin heavy chain gene locus according to BIOMED-2 protocols revealed clonality in 2/10 and 6/10 cases, respectively.

*Expression of microRNAs in chronic gastritis and MALT lymphoma samples*. All microRNAs investigated in the current study were shown to be constitutively expressed in gastric biopsy specimen biopsies in all cases included in the study (n=59).

*Changes in microRNA expression signatures concur with malignant transformation from chronic H. pylori-associated gastritis to MALT lymphoma*. MicroRNA signatures differ significantly between gastric biopsies with different Wotherspoon scores. In summary, four of the investigated microRNAs showed altered expression levels from score 0 to 5. Out of these, expression levels of two microRNAs decreased (miR-150 and miR142-3p), whereas expression levels of two microRNAs increased (miR-375 and miR-474) (see Table IV and Figure 1).

Comparative analysis of gastritis (Wotherspoon scores 1, 2, and polyclonal 3, 4) and MALT lymphoma (Wotherspoon score 5 and monoclonal scores 3 and 4) showed four microRNAs, namely miR-150, miR-494, miR-124a and miR-142-3p, to be differentially expressed after adjusting for multiple testing (see Table V and Figure 2).

## Discussion

Extranodal marginal zone lymphoma of MALT type is recognized as a distinct entity by the WHO classification and is in many instances associated with chronic antigenic stimulus and chronic inflammation (2). Pathogenetically, both infection (*H. pylori* and *Chlamydia psitaci*) and autoimmune disorders, such as Sjögren syndrome and Hashimoto thyroiditis, has been shown to be of relevance. The causal link between an inflammatory stimulus and B-cell lymphomagenesis is best established for gastric MALT lymphomas and *H. pylori* (5). Seeking to validate and verify our initial findings of miR-150, miR-550, miR- 124a, miR-518b and miR-539 being differentially expressed in gastritis as opposed to MALT lymphoma, we performed RT-PCR-based expression profiling of 20 microRNAs selected due to their previously published expression levels in an independent cohort of 60 gastric MALT lymphomas (17). Deviating from the initial setting normalization was performed by applying the deltaCT method using the

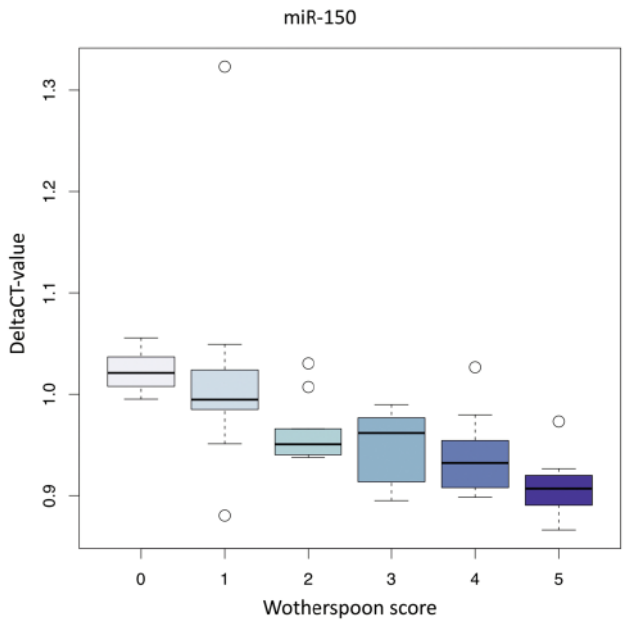


Figure 1. *Trend in CT values for different groups of Wotherspoon score for miR-150. Boxes range from 25th to 75th percentile and include median values. Whiskers indicate range and circles display outliers.*

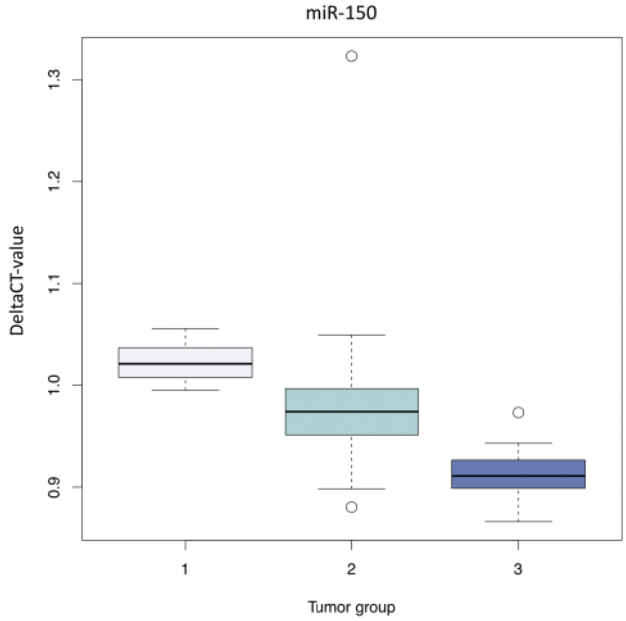


Figure 2. *Boxplots for pooled groups (1 - normal, 2 - gastritis and 3 – gastric mucosa associated lymphoid tissue lymphoma) and miR-150. Boxes range from 25th to 75th percentile and include median values. Whiskers indicate range and circles display outliers.*

Table IV. *Significant microRNAs (Wotherspoon groups), median difference (ΔCT values) for groups 0 and 5 with corresponding confidence interval (CI) and unadjusted p-value.*

| miRNA | Median difference | CI | Unadjusted *p*-Value |
|---|---|---|---|
| miR-150 | 0.12 | 0.09-0.14 | 3.98e-09 |
| miR-142.3p | 0.15 | 0.13-0.18 | 5.13e-07 |
| miR-375 | –0.08 | –0.13-–0.04 ] | 2.70e-05 |
| miR-494 | –0.06 | –0.09-–0.04 | 9.40e-04 |

Table V. *Significant microRNAs (pooled groups), median difference (ΔCT-values) for groups 2 and 3 (see Table III) with corresponding confidence interval (CI) and unadjusted p-value.*

| miRNA | Median difference | CI | Unadjusted *p*-Value |
|---|---|---|---|
| miR-150 | 0.06 | 0.04-0.18 | 4.07e-07 |
| miR-142.3p | 0.09 | 0.05-0.12 | 1.55e-05 |
| miR-494 | –0.06 | –0.08-–0.03 | 9.13e-05 |
| miR-124a | –0.05 | –0.08-–0.02 | 1.64e-03 |

quantitative expression of *RNU6* as a housekeeping microRNA. In the current study, we were able to reproduce our initial findings of an increased expression of miR-150. The aberrantly-elevated expression of miR-150 remains remarkable in the light of this microRNAs previously postulated role as a tumor suppressor in the hematopoietic system. We were able to identify significant down-regulation of miR-150 in diffuse large B-cell lymphoma but not

follicular lymphoma (20-22). Thus, miR-150 was expected to be down-regulated in lymphoma (23-26). Recently, Monsalvez *et al*. identified a similar phenomenon in primary cutaneous marginal zone lymphoma, however, the authors found low levels of miR-150 to be associated with shortened overall survival (27). Moreover, Cai *et al*. made corresponding observations for primary conjuctival MALT lymphoma (28). This leaves room for speculation as to the functional consequences of increased miR-150 expression as it appears to be a molecular hallmark of marginal zone lymphomas regardless of their site of primary manifestation, while at the same time it positively affects patient outcome. The role of miR-150 as a key regulatory element in the differentiation of B- and T-cells has been established in the past. In light of our present findings, alongside previously published results from Wu *et al*. describing high miR-150 expression in gastric carcinoma, we reason that the localization of a malignant tumor may vitally influence the oncogenic or tumor-suppressive behavior of miR-150 (25). Our initial findings regarding aberrant expression of miR-550, miR- 124a, miR-518b and miR-539 failed to reach statistical significance in the current study, indicating a variable degree of contribution to MALT lymphoma pathogenesis. Unlike the results obtained in our initial study, we here demonstrate miR142-3p as another microRNA significantly increased in expression, whereas miR-375 and miR-474 decreased in expression. These findings had merely bordered on statistical significance in our previous investigations. Integrating results from both cohorts, a role of these microRNAs can be presumed. Further studies, integrating functional analyses, are needed in order to validate this assumption. In summary, we were able to underline the pathogenetic implications of miR-150 in gastric extranodal marginal zone lymphomas and its pre-malignant precursor lesions, as elevated expression was detectable in both our initial study as well as the present validation study employing modified methodology and statistical normalization approaches. Although these findings emphasize on the role of miR-150 as an oncomiR in gastric MALT lymphoma, they also necessitate the elucidation of molecular mechanisms by which miR-150 drives malignant transformation of pre-neoplastic lymphocytic lesions. It is tempting to speculate about a potential implication for novel targeted therapy approaches.

## Declaration of Interests

The Authors declare that there are no financial or other potential conflicts relevant to the manuscript.

## Acknowledgements

This work was supported by Deutsche Forschungsgemeinschaft" Grant-No. TH 813/4-1 to C.T. We thank Annette Aufseß for excellent technical assistance.

## References

1 Ullrich A, Fischbach W and Blettner M: Incidence of gastric B-cell lymphomas: a population-based study in Germany. Ann Oncol *13*: 1120-1127, 2002.

2 Swerdlow SH: WHO Classification of Tumors of Haematopoetic and Lymphoid Tissues: WHO, IARC 2008.

3 Thieblemont C, Bastion Y, Berger F, Rieux C, Salles G, Dumontet C, Felman P and Coiffier B: Mucosa-associated lymphoid tissue gastrointestinal and nongastrointestinal lymphoma behavior: analysis of 108 patients. J Clin Oncol *15*: 1624-1630, 1997.

4 Hussell T, Isaacson PG, Crabtree JE and Spencer J: The response of cells from low-grade B-cell gastric lymphomas of mucosa-associated lymphoid tissue to *Helicobacter pylori*. Lancet *342*: 571-574, 1993.

5 Wotherspoon AC, Doglioni C, Diss TC, Pan L, Moschini A, de Boni M and Isaacson PG: Regression of primary low-grade B-cell gastric lymphoma of mucosa-associated lymphoid tissue type after eradication of *Helicobacter pylori*. Lancet *342*: 575-577, 1993.

6 Cerroni L, Zochling N, Putz B and Kerl H: Infection by *Borrelia burgdorferi* and cutaneous B-cell lymphoma. J Cutan Pathol *24*: 457-461, 1997.

7 Noack F, Lange K, Lehmann V, Caselitz J and Merz H: Primary extranodal marginal zone B-cell lymphoma of the fallopian tube. Gynecol Oncol *86*: 384-386, 2002.

8 Hummel M, Oeschger S, Barth TF, Loddenkemper C, Cogliatti SB, Marx A, Wacker HH, Feller AC, Bernd HW, Hansmann ML, Stein H and Moller P: Wotherspoon criteria combined with B cell clonality analysis by advanced polymerase chain reaction technology discriminates covert gastric marginal zone lymphoma from chronic gastritis. Gut *55*: 782-787, 2006.

9 Wotherspoon AC, Ortiz-Hidalgo C, Falzon MR and Isaacson PG: *Helicobacter pylori*-associated gastritis and primary B-cell gastric lymphoma. Lancet *338*: 1175-1176, 1991.

10 Fischbach W, Goebeler-Kolve ME, Dragosics B, Greiner A and Stolte M: Long term outcome of patients with gastric marginal zone B cell lymphoma of mucosa associated lymphoid tissue (MALT) following exclusive *Helicobacter pylori* eradication therapy: experience from a large prospective series. Gut *53*: 34-37, 2004.

11 Liu H, Ruskon-Fourmestraux A, Lavergne-Slove A, Ye H, Molina T, Bouhnik Y, Hamoudi RA, Diss TC, Dogan A, Megraud F, Rambaud JC, Du MQ and Isaacson PG: Resistance of t(11;18) positive gastric mucosa-associated lymphoid tissue lymphoma to *Helicobacter pylori* eradication therapy. Lancet *357*: 39-40, 2001.

12 Lee RC, Feinbaum RL and Ambros V: The C. elegans heterochronic gene lin-4 encodes small RNAs with antisense complementarity to lin-14. Cell *75*: 843-854, 1993.

13 Bartel DP: MicroRNAs: genomics, biogenesis, mechanism, and function. Cell *116*: 281-297, 2004.

14 Calin GA, Sevignani C, Dan Dumitru C, Hyslop T, Noch E, Yendamuri S, Shimizu M, Rattan S, Bullrich F, Negrini M and Croce CM: Human microRNA genes are frequently located at fragile sites and genomic regions involved in cancers. P Natl Acad Sci USA *101*: 2999-3004, 2004.

15 Matsushima K, Isomoto H, Inoue N, Nakayama T, Hayashi T, Nakayama M, Nakao K, Hirayama T and Kohno S: MicroRNA signatures in *Helicobacter pylori*-infected gastric mucosa. Int J Cancer *128*: 361-370, 2011.

16 Calin GA, Ferracin M, Cimmino A, Di Leva G, Shimizu M, Wojcik SE, Iorio MV, Visone R, Sever NI, Fabbri M, Iuliano R, Palumbo T, Pichiorri F, Roldo C, Garzon R, Sevignani C, Rassenti L, Alder H, Volinia S, Liu CG, Kipps TJ, Negrini M and Croce CM: A MicroRNA signature associated with prognosis and progression in chronic lymphocytic leukemia. N Engl J Med *353*: 1793-1801, 2005.

17 Thorns C, Kuba J, Bernard V, Senft A, Szymczak S, Feller AC and Bernd HW: Deregulation of a distinct set of microRNAs is associated with transformation of gastritis into MALT lymphoma. Virchows Arch *460*: 371-377, 2012.

18 Saito Y, Suzuki H, Tsugawa H, Imaeda H, Matsuzaki J, Hirata K, Hosoe N, Nakamura M, Mukai M, Saito H and Hibi T: Overexpression of miR-142-5p and miR-155 in gastric mucosa-associated lymphoid tissue (MALT) lymphoma resistant to *Helicobacter pylori* eradication. PLoS One *7*: e47396, 2012.

19 van Dongen JJ, Langerak AW, Bruggemann M, Evans PA, Hummel M, Lavender FL, Delabesse E, Davi F, Schuuring E, Garcia-Sanz R, van Krieken JH, Droese J, Gonzalez D, Bastard C, White HE, Spaargaren M, Gonzalez M, Parreira A, Smith JL, Morgan GJ, Kneba M and Macintyre EA: Design and standardization of PCR primers and protocols for detection of clonal immunoglobulin and T-cell receptor gene recombinations in suspect lymphoproliferations: report of the BIOMED-2 Concerted Action BMH4-CT98-3936. Leukemia *17*: 2257-2317, 2003.

20 Xiao C, Calado DP, Galler G, Thai TH, Patterson HC, Wang J, Rajewsky N, Bender TP and Rajewsky K: MiR-150 controls B cell differentiation by targeting the transcription factor c-Myb. Cell *131*: 146-159, 2007.

21 Roehle A, Hoefig KP, Repsilber D, Thorns C, Ziepert M, Wesche KO, Thiere M, Loeffler M, Klapper W, Pfreundschuh M, Matolcsy A, Bernd HW, Reiniger L, Merz H and Feller AC: MicroRNA signatures characterize diffuse large B-cell lymphomas and follicular lymphomas. Br J Haematol *142*: 732-744, 2008.

22 Ghisi M, Corradin A, Basso K, Frasson C, Serafin V, Mukherjee S, Mussolin L, Ruggero K, Bonanno L, Guffanti A, De Bellis G, Gerosa G, Stellin G, D'Agostino DM, Basso G, Bronte V, Indraccolo S, Amadori A and Zanovello P: Modulation of microRNA expression in human T-cell development: targeting of Notch3 by miR-150. Blood 2011.

23 Gebauer N, Bernard V, Gebauer W, Feller AC and Merz H: MicroRNA Expression and JAK2 Allele Burden in Bone Marrow Trephine Biopsies of Polycythemia Vera, Essential Thrombocythemia and Early Primary Myelofibrosis. Acta Haematol *129*: 251-256, 2013.

24 Watanabe A, Tagawa H, Yamashita J, Teshima K, Nara M, Iwamoto K, Kume M, Kameoka Y, Takahashi N, Nakagawa T, Shimizu N, and Sawada K: The role of microRNA-150 as a tumor suppressor in malignant lymphoma. Leukemia 2011.

25 Wu Q, Jin H, Yang Z, Luo G, Lu Y, Li K, Ren G, Su T, Pan Y, Feng B, Xue Z, Wang X and Fan D: MiR-150 promotes gastric cancer proliferation by negatively regulating the pro-apoptotic gene EGR2. Biochem Biophys Res Commun *392*: 340-345, 2010.

26 Zhao JJ, Lin J, Lwin T, Yang H, Guo J, Kong W, Dessureault S, Moscinski LC, Rezania D, Dalton WS, Sotomayor E, Tao J and Cheng JQ: microRNA expression profile and identification of miR-29 as a prognostic marker and pathogenetic factor by targeting CDK6 in mantle cell lymphoma. Blood *115*: 2630-2639, 2010.

27 Monsalvez V, Montes-Moreno S, Artiga MJ, Rodriguez ME, Espiridion BS, Lozano M, Fernandez-de-Misa R, Rodriguez-Peralto JL, Piris MA and Ortiz-Romero PL: MicroRNAs as prognostic markers in indolent primary cutaneous B-cell lymphoma. Mod Pathol *26*: 617, 2013.

28 Cai J, Liu X, Cheng J, Li Y, Huang X, Ma X, Yu H, Liu H and Wei R: MicroRNA-200 is commonly repressed in conjunctival MALT lymphoma, and targets cyclin E2. Graefes Arch Clin Exp Ophthalmol *250*: 523-531, 2012.

*Received January 29, 2014*
*Revised February 17, 2014*
*Accepted February 18, 2014*